Réseau de cancérologie Rossy
Rossy Cancer Network

Radiomics with artificial intelligence for detection of cervical nodal metastases

Reza Forghani, MD, PhD, Caroline Reinhold, MD, MSc, Michael Hier, MD, Nader Sadeghi, MD, Alex M. Mlynarek, MD, MSc, Alan Spatz, MD, PhD, Jan Seuntjens, PhD, Avishek Chatterjee, PhD, Jaron Chong, MD, Khalil Sultanem, MD, Keith Richardson, MD, Jeffrey Chankowsky, MD, Behzad Forghani, MEng

CQI Research Grant 2016

INTRODUCTION

Detection and accurate characterization of metastatic cervical lymphadenopathy is essential for optimal staging and management of patients with head and neck squamous cell carcinoma (HNSCC).

Despite significant improvements in the identification of metastatic cervical lymph nodes with currently used imaging techniques, commonly used criteria have overall error rates of 15 to 20% or more for the determination of cervical lymphadenopathy.

As a result, HNSCC patients with clinically N0 neck harboring tumours at high risk sites routinely undergo neck dissections, even if this could result in overtreatment of a significant percentage of this patient population.

We hypothesize that radiomic models combined with machine learning for construction of prediction models can improve non-invasive detection and characterization of nodal metastases, with the potential to improve patient care and quality of life by reducing unnecessary elective neck dissections or the extent of neck dissections.

OBJECTIVES

1. Develop and validate predictive radiomic models for identification of nodal metastases using pre-surgical clinico-pathologic parameters and texture analysis with machine learning.
2. Correlate advanced image texture characteristics and tumour molecular profile to develop non-invasive radiogenomic signatures using AI for identification and risk stratification of early nodal metastases in the neck.

METHODS / INTERVENTIONS

- Prediction models were constructed for determination of cervical nodal metastases using (1) primary tumour texture features and (2) texture analysis of lymph nodes.
- 2D texture analysis was performed on dual-energy CT (DECT) scans using a commercially available software (TexRAD Ltd, Cambridge, United Kingdom).
- We evaluated performance using texture features extracted from (1) only 65 keV virtual monochromatic images (VMIs), typically considered similar to a standard single energy CT or (2) multi-energy VMIs ranging from 40 to 140 keV in 5 keV increments generated from the same DECT scan.
- The Random Forests (RF) method was used to build the prediction models. For some models, a second independent machine learning approach (Gradient Boosting Machine; GBM) was also used. Randomly selected, independent training and testing sets were used for construction of prediction models and generation of receiver operating curves.
- Radiomic models combining image texture features and routine parameters (e.g. tumour size) were also tested to evaluate for redundancy and help create the most optimal model.
- HNSCC biobank samples are being prospectively collected for transcriptome analysis and future incorporation and construction of non-invasive radiogenomic signatures using AI.

RESULTS

Evaluation of primary tumour texture features for prediction of associated nodal metastasis

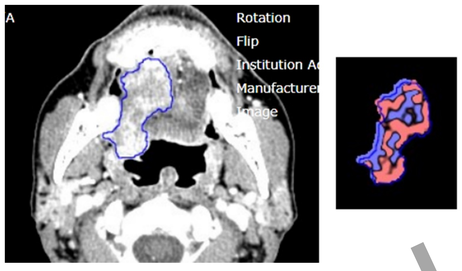

Fig. 1. Example of 2D texture analysis of primary HNSCC tumour. The caption on the left demonstrates segmentation of the tumour. The image on the right is an example of a 2D texture map.

Using texture analysis on baseline DECT scans of untreated HNSCC patients (n = 64), texture features extracted from 65 keV VMIs had an accuracy, sensitivity, specificity, positive predictive value, and negative predictive value of 63%, 70%, 56%, 64%, and 63%, respectively.

On the other hand, texture analysis of multi-energy VMIs generated from the same scans had a much better performance, with an accuracy, sensitivity, specificity, positive predictive value, and negative predictive value of 84%, 80%, 89%, 89%, and 80%. Two texture features were used in the final prediction model. There was minimal additional benefit from inclusion of other parameters such as texture analysis of iodine-water DECT material decomposition maps, patient's sex, or tumour size measured separately in 3 planes.

Evaluation of texture features of lymph nodes for nodal characterization

Texture analysis of nodes (n = 412) had a high performance for distinguishing metastatic HNSCC from benign nodes or other pathology using two different machine learning approaches, RF and GBM. For distinction of metastatic HNSCC from normal nodes, in the independent testing (prediction) set, there was an accuracy, sensitivity, specificity, PPV, and NPV of 85%, 89%, 82%, 80%, and 90%, respectively, using RF and 90%, 89%, 91%, 89%, and 91%, respectively, using GBM (Fig. 2).

Fig. 2.

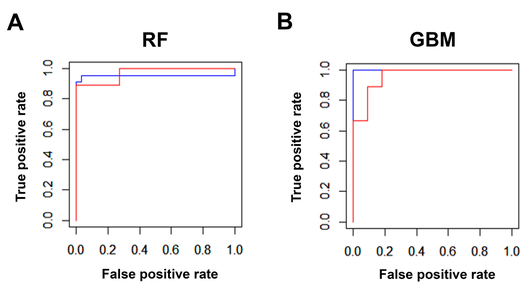

The accuracy, sensitivity, specificity, PPV, and NPV for distinguishing metastatic HNSCC from lymphoma nodes in the prediction set was 93%, 78%, 100%, 100%, and 90%, respectively, using RF or 89%, 78%, 95%, 88%, and 90%, respectively, using GBM

THE NEXT PHASE

- Combine primary tumour texture features, nodal texture features, and other clinico-pathological parameters for prediction model construction.
- Perform a focused study for identification of early metastases (micrometastases) in radiologically "normal" appearing nodes.
- Expand to additional institutions for large scale validation, and perform image analysis and prediction model generation using deep learning.
- Perform radiogenomic studies for endpoint prediction and develop non-invasive radiogenomic signatures as biomarkers.

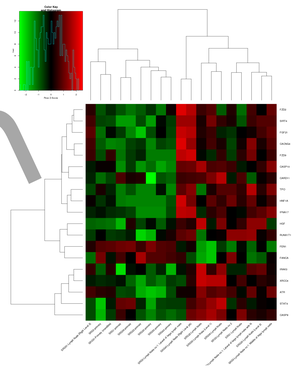

Fig. 3. Heatmap of significant genes from DE paired analyses of primary tumours vs metastatic lymph nodes.

PATIENT IMPACT

If these results are validated in larger studies with independent samples, they could form the basis of clinical assistant tools enabling non-invasive diagnostic evaluation beyond what is currently done in clinical practice. This could lead to more accurate diagnosis, a reduction in unnecessary neck dissections or extent of neck dissections with a concomitant reduction in associated morbidity, and ultimately more precise, personalized therapy.

CONCLUSION

Radiomic analysis with machine learning can be used for identification and characterization of metastatic HNSCC nodes with a high accuracy.

If validated in larger samples using different techniques, the results of this pilot study have the potential to form the basis for clinical assistant diagnostic tools that will improve non-invasive pre-treatment diagnostic evaluation of HNSCC and associated lymphadenopathy.

TRANSLATION ACROSS THE RCN

We are already in the process of expanding this project from a single site to a multi-site study that includes the Jewish General Hospital and McGill University Health Centre. Furthermore, the approaches developed and applied are generalizable and can be applied to other diseases.

McGill
Centre universitaire de santé McGill
McGill University Health Centre
Hôpital général juif
Jewish General Hospital
Centre hospitalier de St. Mary
St. Mary's Hospital Center