

## REVIEW ARTICLE

# Caudal blocks

Martin Jöhr<sup>1</sup> & Thomas M. Berger<sup>2</sup>

<sup>1</sup> Pediatric Anesthesia, Department of Anesthesia, Kantonsspital, Luzern, Switzerland

<sup>2</sup> Neonatal and Pediatric Intensive Care Unit, Children's Hospital, Luzern, Switzerland

### Keywords

Caudal; epidural; anesthesia; children; test dose; complication

### Correspondence

Martin Jöhr,  
Institut für Anästhesie, Kantonsspital,  
6004 Luzern, Switzerland  
Email: joehrmartin@bluewin.ch

Section Editor: Per-Arne Lonnqvist

Accepted 6 July 2011

doi:10.1111/j.1460-9592.2011.03669.x

### Indication, risk, and benefit

#### Caudal block or peripheral nerve block

All types of surgery below the umbilicus can be covered by a caudal block: 'one technique fits all'. This is relevant, because not all anesthesiologists are familiar with the necessary spectrum of peripheral nerve blocks in children. On the other hand, peripheral nerve blocks provide prolonged analgesia restricted to the site of surgery and should be preferred, e.g., penile block for circumcision or sciatic nerve block for podiatric surgery.

The main goal of caudal block is to provide postoperative pain relief, and it is accepted that the block is performed in anesthetized children (7). By using morphine, even upper abdominal and thoracic incisions can be covered. However, some experts use caudal analgesia as the primary anesthetic technique in fully awake (8) or in slightly sedated infants (9), e.g., for inguinal hernia repair.

### Safety

Single-shot caudal anesthesia is remarkably safe: In a retrospective audit reporting on more than 158 000 patients, there was no report of permanent damage (2), and two well done prospective studies examining 12 111 (10) and 8493 (11) caudals, respectively, showed

Caudal anesthesia is the single most important pediatric regional anesthetic technique. The technique is relatively easy to learn (1), has a remarkable safety record (2), and can be used for a large variety of procedures. The technique has been reviewed in the English (3) and French (4) literature, as well as in German guidelines (5) and in pediatric anesthesia textbooks (6).

the same beneficial results. In general, neuraxial blocks have a higher number of side effects and complications compared with peripheral nerve blocks, but, remarkably, there is not a single case of epidural abscess, epidural hematoma, or paraplegia after a single-shot caudal block in world's literature. This in contrast to other neuraxial techniques in children, e.g., with thoracic epidural anesthesia where three cases with severe neurologic damage (12–14) have been reported despite the fact that this technique is rarely used in children.

Complications such as total spinal anesthesia are possible, but all were successfully managed (15–17). Local pain at the injection site or back pain has been discussed (18), but this is not a relevant problem in clinical practice. Similarly, the occurrence of urinary retention could be more common with a caudal block (19), but the authors have not seen a single child needing bladder catheterization in the absence of neuraxial opioids or preceding penile or bladder surgery.

### Anatomic and physiologic considerations

#### Anatomic considerations

The dura and the spinal cord reach lower levels in the spinal canal in infants (spinal cord L3 at birth, L1/L2 at 1 year and dura S4 at birth, S2 at 1 year). In small infants, the end of the dural sac can be in a distance

of only a few millimeters from the puncture site (20). In children before school age, the loose epidural fat facilitates an even spread of local anesthetics up to the thoracic region. In older children, weighing more than 20 kg, a thoracic spread is more difficult to achieve and caudal block is usually not the first choice for anything but the lowest of abdominal incision.

### Hemodynamic changes

It has been stated that up to the age of 6–8 years even a high spinal (21) or epidural (22) block causes only minimal cardiovascular changes because of the relatively low basal sympathetic tone in this age range. Moderate blood pooling and vasodilatation in the lower part of the body (23) are counteracted by vasoconstriction in other areas of the body (24). However, individual patients, especially neonates and small infants with combined caudal and general anesthesia, can experience profound hypotension after a caudal block (Figure 1).

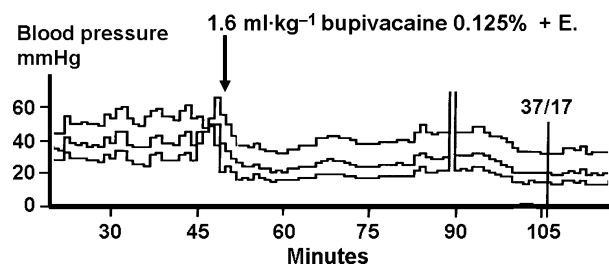
### Technique and material

#### Positioning

After induction of general anesthesia, a left lateral position is obtained with the upper hip flexed 90° and the lower one only 45°. Alternatively, the prone position can be used. In fully awake newborns, caudal block is best performed with the baby in prone position.

#### Disinfection

Before palpating the landmarks, the region is swabbed in a cranio-caudal direction with 70% alcohol solution



**Figure 1** Hemodynamic changes can occur: Profound hypotension induced by the caudal injection of  $1.6 \text{ ml}\cdot\text{kg}^{-1}$  of bupivacaine 0.125% with epinephrine in a 2700-g neonate presenting for the removal of a large ovary cyst under combined caudal and general anesthesia. The patient's lung was ventilated with air and oxygen and stable endtidal sevoflurane concentration of 1.5 Vol.%. The hypotension was treated with volume boluses and dopamine; the secondary drop of blood pressure at around 100 min followed surgical bleeding.

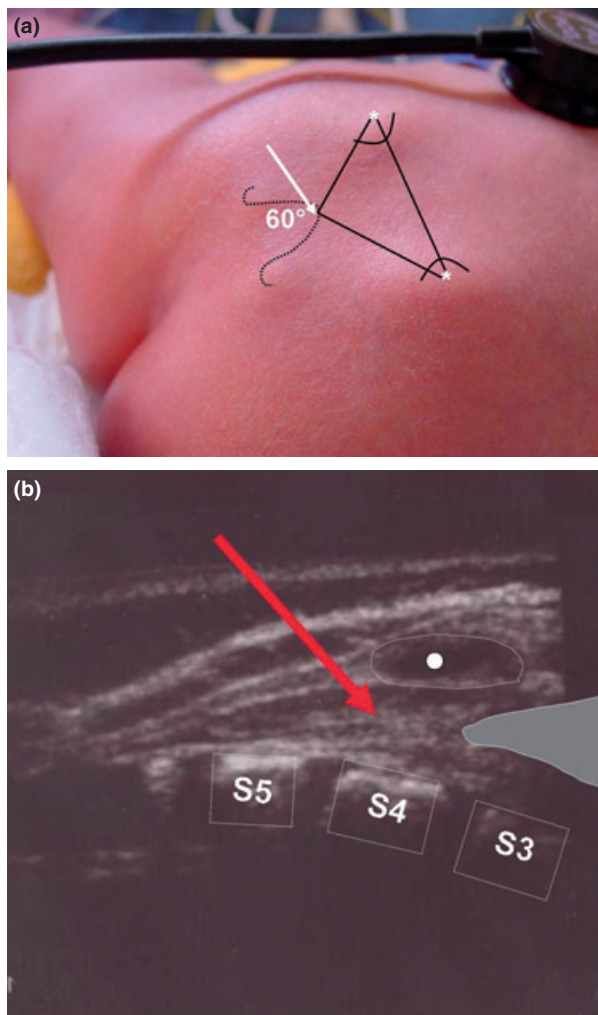
to reduce the amount of bacteria. Intensive disinfection with an alcoholic solution (25,26), sterile drapes, and the use of sterile gloves should be standard for every neuraxial blockade. A case of sacral osteomyelitis has been reported after the use of the watery disinfection solution octenidinum (27).

### Landmarks

The upper posterior iliac spine and the sacral hiatus form the edges of an equilateral triangle. Epidural puncture is achieved in the most proximal region of the sacral hiatus with the needle inclined 45–60° to the skin. The palpating index finger of the left hand lies on the spinous process S4 (Figure 2). The needle should be inserted just below the spinous process S4. After perforation of the membrane, which occludes the sacral hiatus, the needle should only be minimally advanced, not more than 1–3 mm, in order to avoid a bloody puncture or an intrathecal injection (28). The distance between the dural sac and the puncture site can be remarkably short (20) and accidental intrathecal injections with total spinal anesthesia do occur (15–17). In the authors' institution, an incidence of approximately 1 : 1500 has been seen. With flexion of the spine, the end of the dural sack moves cranially (29), thus increasing the margin of safety. Up to 1 year of age, the correct epidural spread can be easily visualized by ultrasound (30). However, this is mainly for teaching benefits and should, in the view of the authors, not be part of the clinical routine.

### Equipment

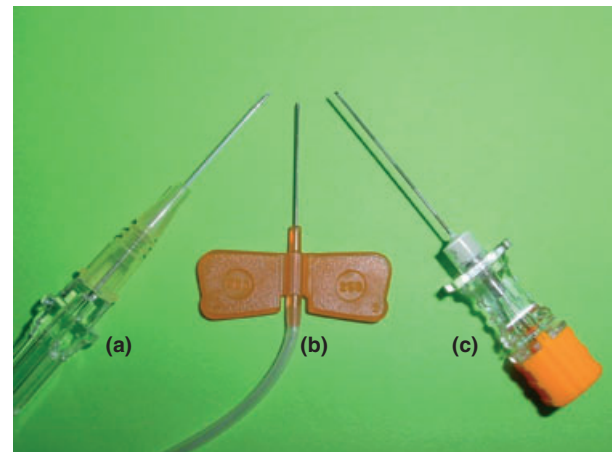
Different types of needles and cannulae are currently in use (31). Normal hypodermic needles have a long tradition and are still used; some authorities argue that this practice could be unsafe because of the risk of spreading epidermal cells into the spinal canal (32). This has been shown to be a problem in the case of lumbar puncture (33), but no such reports have been published yet after epidural injections. With modern needles, the amount of tissue coring seems to be identical with the different types of needles (34). Specially designed caudal needles with a short bevel and a stylet are a good choice and probably reduce the risk of vascular puncture (35). Plastic i.v. cannulas or lumbar puncture needles are also used (Figure 3). In any case, the type of needle used should not be bigger than 25G: a fine needle causes less trauma. The caudal needle from BRAUN® with extension tubing allows an immobile needle technique.



**Figure 2** Anatomy of the sacral area. (a) The point of needle insertion in the apex of sacral hiatus. The baby is in prone position with the left lower limb in the top left-hand corner. (b) A sonographic view illustrating the short distance to the dural sac in this patient. The arrow illustrates the path of the needle. The cartilaginous spinous process S4 is marked .

### Caudal catheters

By using a plastic cannula or even a Tuohy needle, it is technically easy to insert a catheter via the sacral hiatus and use it for intraoperative or postoperative pain relief. The proximity of the anal region raises concerns about the risk of bacterial contamination (36), and special precautions have to be taken; some experts advise tunneling caudal catheters (37). In larger series, no severe infections have been reported (38), and the method seems to be safe. However, an increased incidence of colonization of caudal catheters with gram-negative bacteria has been described (36,39). Furthermore, most reported septic (40–42) or



**Figure 3** Commonly used needles for caudal block: (a) 24-G intravenous cannula (b) 25-G 'butterfly' needle (c) 25-G graduated special caudal needle.

technical (43) complications in connection with pediatric epidural anesthesia occurred with continuous techniques and not with single-shot caudal injections. It is therefore the authors' strong belief that caudal catheters should only be used in selected cases.

Bösenberg *et al.* (44) described the insertion of caudal catheters up to a high thoracic level ('*caudo-thoracic anesthesia*'); this was confirmed by others (45). However, this technique is only reliably successful when large-bore catheters (44) or catheters with a stylet (45) are used and malpositioning (46) does occur. Typically, the position of the catheter tip is confirmed by radiography (47), ultrasound (48), ECG tracing (49), or electrostimulation (50). By using a lumbar approach and ordinary catheters without a stylet, the tip of the catheter cannot be positioned reliably at a thoracic level (51).

### Drugs and dosage

#### Local anesthetics

*Ropivacaine* 0.2% is well suited for caudal anesthesia in children. Compared with bupivacaine, it provides a similar duration of analgesia, but with a reduced incidence of motor blockade. Less severe toxicity may be expected in case of massive intravascular injection. *Bupivacaine* has been thoroughly studied, and a large global experience exists. A concentration of 0.125% is sufficient to provide postoperative pain relief without significant motor blockade (52). Slightly higher concentrations may be used for allowing very light general anesthesia during surgery (53). Therefore, considering the potency of the two drugs, *ropivacaine* 0.2% may be just right.

**Table 1** Dosage for caudal anesthesia

Site of incision	Dosage (ml·kg <sup>-1</sup> )	Drug
Penile or anal surgery	0.5–0.75	Ropivacaine 0.2% or bupivacaine/
Lower extremity	1.0	levobupivacaine
Abdominal incision	1.0–1.25	0.125–0.175%

It is the authors' practice, for the occasional infant, where a caudal block is used as sole anesthetic, to administer 1–1.2 ml·kg<sup>-1</sup> of *bupivacaine* 0.25% with epinephrine or in children a 1 : 1 mixture of 0.25% *bupivacaine* with 1% *prilocaine*.

A dose of roughly 1 ml·kg<sup>-1</sup> is adequate for most indications. The volume is usually restricted to 25 ml. Caudal injections using local anesthetics are not recommended for abdominal incisions in children weighing more than 25 kg (Table 1).

Recently, several attempts have been made to correlate the size of the patient with the anatomic spread evaluated by X-ray (54,55) or ultrasound (56). The anatomic spread, however, only weakly correlates with the clinical extension of the blockade.

*Bupivacaine*, *levobupivacaine*, and *ropivacaine* are all suitable local anesthetics. In clinical practice, the use of the least toxic drug only marginally increases safety as most complications occur because of a massive intravascular injection or because of major mistakes, e.g., injecting *ropivacaine* 1% (57) or 0.75% (11) instead of 0.2%. Overall, local anesthetics have a good safety record in pediatric anesthesia; in the American Perioperative Cardiac Arrest (POCA) Registry (58,59), only a minority, 7 of 343, of all children arrested because of an accident related to local anesthetics.

### Adjuvants

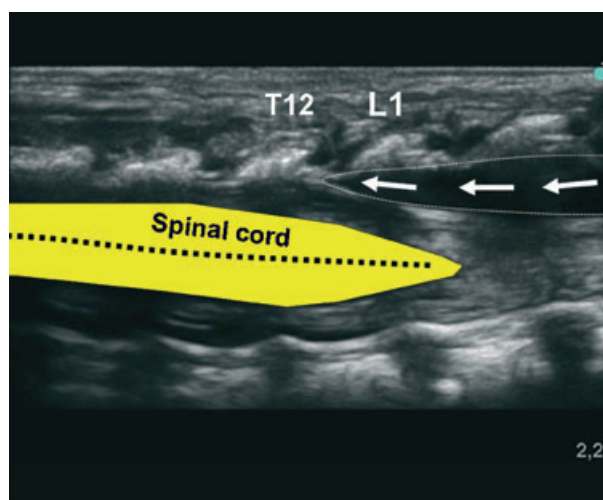
Adjuvants are used to prolong the duration of analgesia (60,61). *Epinephrine* (5 µg·ml<sup>-1</sup>) prolongs the duration of action of caudal epidural *bupivacaine* in infants and allows the detection of intravascular needle placement (62) and should be used, at least with the test dose. The local anesthetic alone without epinephrine does not cause reliable ECG changes (63). It is the authors' practice to inject 0.5–1 µg·kg<sup>-1</sup> *epinephrine* in 0.1–0.2 ml·kg<sup>-1</sup> of the local anesthetic solution. Although scientific data are missing to support this approach, it should allow the reliable detection of an intravascular injection and the amount of local anesthetic should not cause major harm. As mentioned earlier, in infants, the correct epidural spread, and

therefore the absence of intravascular injection, can be nicely demonstrated by ultrasound (Figure 4).

The addition of *clonidine*, 1–2 µg·kg<sup>-1</sup> – this means in most situations 1–2 µg·ml<sup>-1</sup> – prolongs the duration of analgesia after caudal *bupivacaine*, as shown by several authors (64). The side effects are minimal and not of clinical relevance; however, with higher doses, e.g., 5 µg·kg<sup>-1</sup>, sedation, hypotension, and bradycardia are regularly seen (65). *Clonidine* should be avoided in young infants, as postoperative apnea can occur (66–69). A similar duration of analgesia has also been reported after intravenous administration of *clonidine* (70), but preference should probably be given to the caudal administration because there is a specific segmental neuraxial effect (71). In the authors' practice, *clonidine* is usually not given because of its prolonged sedative effects.

*Morphine* provides excellent, long-lasting analgesia (72). However, side effects are common, such as nausea, urinary retention, pruritus, and respiratory depression (73). Therefore, the role of caudal opioids has recently been questioned (74). But the authors of this review are convinced that for a few exceptional patients, the risk–benefit analysis is still in favor of caudal morphine. The optimal single dose in case of a caudal catheter with the option of redosing seems to be 33–50 µg·kg<sup>-1</sup> (75). For single-shot injections, we use a slightly higher dose, 75–100 µg·kg<sup>-1</sup>, in patients with a urinary catheter and monitor them for at least 12 h in the ICU.

The more lipophilic opioids, such as *fentanyl* (76), *sufentanil* (77), *pethidine* (78), *diamorphine* (79), or



**Figure 4** The correct epidural spread (arrows) can be nicely demonstrated by ultrasound. The anatomic spread up to a T12/L1 level is different to the clinically established height of the blockade.



*tramadol* (80), cause side effects, but do not prolong the duration of analgesia in a clinically relevant way.

The addition of *ketamine* nearly triples the duration of analgesia after caudal *bupivacaine* (81), compared with the plain solution; the optimal dose seems to be 0.5 mg·kg<sup>-1</sup>. Good results have been reported with *S-ketamine*. However, potential neurotoxicity is a problem (82,83), and, similar to *midazolam* or *neostigmine*, *S-ketamine* cannot be recommended for clinical use (84). In fact, before the availability of animal data showing toxicity, ketamine and S-ketamine have been extensively administered caudally to pediatric patients, with no apparent clinical toxicity. However, with the today's knowledge, the authors of this review are convinced that it would be against good practice to continue to promote the use of epidural ketamine.

### Comparison of other regional techniques with caudal block

#### Lumbar and transsacral epidural analgesia

Lumbar epidural anesthesia is relatively easy to perform, especially at the level L4/5 or L5/S1. The epidural space can be identified by loss of resistance to air or saline. However, no or only small amounts of air should be injected into the epidural space. The injection of large amounts of air in small infants has been related to complications (85). Side effects and technical problems do occur; however, the risk of epidural infection seems to be low. In contrast to caudal anesthesia, neurologic complications (86,87) including paraplegia (88) have been reported with the lumbar approach. Lumbar catheters are not suitable to provide analgesia after abdominal or even thoracic procedures using local anesthetics alone.

In pediatric patients, a transsacral (S2/S3) puncture is feasible (89,90); however, this technique also carries the risk of dural puncture, has no advantage compared

with the L5/S1-approach, and has been abandoned by the authors.

#### Ilioinguinal nerve block, penile block

In children weighing more than 20–25 kg, ilioinguinal nerve block is the commonly used alternative to caudal anesthesia for providing analgesia after inguinal incisions. However, in the authors' experience, this technique is less effective and provides less complete analgesia compared to caudal block; in addition, the blind technique without ultrasound carries risks, such as intestinal puncture (91–93) and femoral nerve block (94). Typically, a rapid absorption with high plasma levels occurs (95). The use of ultrasound guidance has meant that more accurate placement of lower doses is now feasible and has led to a resurgence of enthusiasm for regional blocks.

For penile surgery, a penile block is advantageous (96,97), and it provides prolonged analgesia restricted to the site of surgery and is associated with a low complication rate (98). For extensive penile procedures, e.g., hypospadias repair, it is the authors' practice to combine caudal anesthesia (profound intraoperative analgesia) with a penile block (prolonged analgesia) (6).

### Conclusions

Caudal block continues to be a great technique. It is a simple, safe, and effective way to provide pain relief after interventions below the umbilicus.

### Acknowledgments

This research was carried out without funding.

### Conflict of interest

No conflicts of interest declared.

### References

- Schuepfer G, Konrad C, Schmeck J *et al.* Generating a learning curve for pediatric caudal epidural blocks: an empirical evaluation of technical skills in novice and experienced anesthetists. *Reg Anesth Pain Med* 2000; **25**: 385–388.
- Gunter J. Caudal anesthesia in children: a survey. *Anesthesiology* 1991; **75**: A936.
- Rowney DA, Doyle E. Epidural and subarachnoid blockade in children (Review article). *Anaesthesia* 1998; **53**: 980–1001.
- Murat I. Anesthésie locorégionale chez l'enfant. Conférence d'experts (Congrès Sfar 1997). *Ann Fr Anesth Reanim* 1997; **16**: 985–1029.
- Mader T, Hornung M, Boos K *et al.* Handlungsempfehlungen zur Regionalanästhesie bei Kindern. *Anästhesiol Intensivmed* 2007; **48**: S79–S85.
- Jöhr M. *Kinderanästhesie*. 7. ed. München: Elsevier, 2009.
- Krane EJ, Dalens BJ, Murat I *et al.* The safety of epidurals placed during general anesthesia (editorial). *Reg Anesth Pain Med* 1998; **25**: 433–438.
- Hoelzle M, Weiss M, Dillier C *et al.* Comparison of awake spinal with awake caudal anesthesia in preterm and ex-preterm infants for herniotomy. *Pediatr Anesth* 2010; **20**: 620–624.
- Brenner L, Kettner SC, Marhofer P *et al.* Caudal anaesthesia under sedation: a prospective analysis of 512 infants and children. *Br J Anaesth* 2010; **104**: 751–755.
- Giaufre E, Dalens B, Gombert A. Epidemiology and morbidity of regional anesthesia in children: a one-year prospective survey of the French-language society of pediatric anesthesiologists. *Anesth Analg* 1996; **83**: 904–912.

- 11 Ecoffey C, Lacroix F, Giaufre E *et al.* Epidemiology and morbidity of regional anesthesia in children: a follow-up one-year prospective survey of the French-Language Society of Paediatric Anaesthesiologists (ADARPEF). *Pediatr Anesth* 2010; **20**: 1061–1069.
- 12 Kasai T, Yaegashi K, Hirose M *et al.* Spinal cord injury in a child caused by an accidental dural puncture with a single-shot thoracic epidural needle. *Anesth Analg* 2003; **96**: 65–67.
- 13 Allison CE, Aronson DC, Geukers VG *et al.* Paraplegia after thoracotomy under combined general and epidural anesthesia in a child. *Pediatr Anesth* 2008; **18**: 539–542.
- 14 Aldrete JA, Ferrari H. Myelopathy with syringomyelia following thoracic epidural anaesthesia. *Anaesth Intensive Care* 2004; **32**: 100–103.
- 15 Bouchut JC, Dubois R, Foussat C *et al.* Evaluation of caudal anaesthesia performed in conscious ex-premature infants for inguinal herniotomies. *Pediatr Anesth* 2001; **11**: 55–58.
- 16 Desparmet JF. Total spinal anesthesia after caudal anesthesia in an infant. *Anesth Analg* 1990; **70**: 665–667.
- 17 Afshan G, Khan FA. Total spinal anaesthesia following caudal block with bupivacaine and buprenorphine. *Pediatr Anesth* 1996; **6**: 239–242.
- 18 Valois T, Otis A, Ranger M *et al.* Incidence of self-limiting back pain in children following caudal blockade: an exploratory study. *Pediatr Anesth* 2010; **20**: 844–850.
- 19 Metzelder ML, Kuebler JF, Glueer S *et al.* Penile block is associated with less urinary retention than caudal anesthesia in distal hypospadias repair in children. *World J Urol* 2010; **28**: 87–91.
- 20 Adewale L, Dearlove O, Wilson B *et al.* The caudal canal in children: a study using magnetic resonance imaging. *Pediatr Anesth* 2000; **10**: 137–141.
- 21 Dohi S, Naito H, Takahashi T. Age-related changes in blood pressure and duration of motor block in spinal anesthesia. *Anesthesiology* 1979; **50**: 319–325.
- 22 Deng M, Wang X, Wang L *et al.* The hemodynamic effects of newborn caudal anesthesia assessed by transthoracic echocardiography: a randomized, double-blind, controlled study. *Pediatr Anesth* 2008; **18**: 1075–1081.
- 23 Hong JY, Ahn S, Kil HK. Changes of dorsalis pedis artery flow pattern after caudal block in children: observational study using a duplex sonography. *Pediatr Anesth* 2010; **21**: 116–120.
- 24 Payen D, Ecoffey C, Carli P *et al.* Pulsed Doppler ascending aortic, carotid, brachial, and femoral artery blood flows during caudal anesthesia in infants. *Anesthesiology* 1987; **67**: 681–685.
- 25 Birnbach DJ, Meadows W, Stein DJ *et al.* Comparison of povidone iodine and Dura-Prep, an iodophor-in-isopropyl alcohol solution, for skin disinfection prior to epidural catheter insertion in parturients. *Anesthesiology* 2003; **98**: 164–169.
- 26 Kinirons B, Mimos O, Lafendi L *et al.* Chlorhexidine versus povidone iodine in preventing colonization of continuous epidural catheters in children: a randomized, controlled trial. *Anesthesiology* 2001; **94**: 239–244.
- 27 Wittum S, Hofer CK, Rolli U *et al.* Sacral osteomyelitis after single-shot epidural anesthesia via the caudal approach in a child. *Anesthesiology* 2003; **99**: 503–505.
- 28 Ivani G. Caudal block: the 'no turn technique'. *Pediatr Anesth* 2005; **15**: 83–84.
- 29 Koo BN, Hong JY, Kim JE *et al.* The effect of flexion on the level of termination of the dural sac in paediatric patients. *Anaesthesia* 2009; **64**: 1072–1076.
- 30 Marhofer P, Bösenberg A, Sitzwohl C *et al.* Pilot study of neuraxial imaging by ultrasound in infants and children. *Pediatr Anesth* 2005; **15**: 671–676.
- 31 Menzies R, Congreve K, Herodes V *et al.* A survey of pediatric caudal extradural anesthesia practice. *Pediatr Anesth* 2009; **19**: 829–836.
- 32 Broadman LM. Where should advocacy for pediatric patients end and concerns for patient safety begin. *Reg Anesth* 1997; **22**: 205–208.
- 33 Batnitzky S, Keucher TR, Mealey J *et al.* Iatrogenic intraspinal epidural tumors. *JAMA* 1977; **237**: 148–150.
- 34 Baris S, Guldogus F, Baris YS *et al.* Is tissue coring a real problem after caudal injection in children. *Pediatr Anesth* 2004; **14**: 755–758.
- 35 Dalens B, Hasnaoui A. Caudal anesthesia in pediatric surgery: success rate and adverse effects in 750 consecutive patients. *Anesth Analg* 1989; **68**: 83–89.
- 36 McNeely JK, Trentadue NC, Rusy LM *et al.* Culture of bacteria from lumbar and caudal epidural catheters used for postoperative analgesia in children. *Reg Anesth* 1997; **22**: 428–431.
- 37 Bubeck J, Boos K, Krause H *et al.* Subcutaneous tunneling of caudal catheters reduces the rate of bacterial colonization to that of lumbar epidural catheters. *Anesth Analg* 2004; **99**: 689–693.
- 38 Strafford MA, Wilder RT, Berde CB. The risk of infection from epidural analgesia in children: a review of 1620 cases. *Anesth Analg* 1995; **80**: 234–238.
- 39 Kost-Byerly S, Tobin JR, Greenberg RS *et al.* Bacterial colonization and infection rate of continuous epidural catheters in children. *Anesth Analg* 1998; **86**: 712–716.
- 40 Emmanuel ER. Post-sacral extradural catheter abscess in a child. *Br J Anaesth* 1994; **73**: 548–549.
- 41 Larsson BA, Lundeberg S, Olsson GL. Epidural abscess in a one-year-old boy after continuous epidural analgesia. *Anesth Analg* 1997; **84**: 1245–1247.
- 42 Meunier JF, Norwood P, Dartayet B *et al.* Skin abscess with lumbar epidural catheterization in infants: is it dangerous? Report of two cases. *Anesth Analg* 1997; **84**: 1248–1249.
- 43 De Armendi AJ, Ryan JF, Chang HM *et al.* Retained caudal catheter in a paediatric patient. *Pediatr Anesth* 1992; **2**: 325–327.
- 44 Bösenberg AT, Bland BA, Schulte-Steinberg O *et al.* Thoracic epidural anesthesia via caudal route in infants. *Anesthesiology* 1988; **69**: 265–269.
- 45 Gunter JB, Eng C. Thoracic epidural anesthesia via the caudal approach in children. *Anesthesiology* 1992; **76**: 935–938.
- 46 van Niekerk J, Bax Vermeire BM, Geurts JW *et al.* Epidurography in premature infants. *Anaesthesia* 1990; **45**: 722–725.
- 47 Taenzer AH, Clark C, Kovarik WD. Experience with 724 epidurograms for epidural catheter placement in pediatric anesthesia. *Reg Anesth Pain Med* 2010; **35**: 432–435.
- 48 Roberts SA, Galvez I. Ultrasound assessment of caudal catheter position in infants. *Pediatr Anesth* 2005; **15**: 429–432.
- 49 Tsui BC, Seal R, Koller J. Thoracic epidural catheter placement via the caudal approach in infants by using electrocardiographic guidance. *Anesth Analg* 2002; **95**: 326–330.
- 50 Tsui BC, Seal R, Koller J *et al.* Thoracic epidural analgesia via the caudal approach in pediatric patients undergoing fundoplication using nerve stimulation guidance. *Anesth Analg* 2001; **93**: 1152–1155.
- 51 Blanco D, Llamazares J, Rincon R *et al.* Thoracic epidural anesthesia via the lumbar approach in infants and children. *Anesthesiology* 1996; **84**: 1312–1316.
- 52 Wolf AR, Valley RD, Fear DW *et al.* Bupivacaine for caudal analgesia in infants and children: the optimal effective concentration. *Anesthesiology* 1988; **69**: 102–106.
- 53 Gunter JB, Dunn CM, Bennie JB *et al.* Optimum concentration of bupivacaine for combined caudal-general anesthesia in children. *Anesthesiology* 1991; **75**: 57–61.
- 54 Koo BN, Hong JY, Kil HK. Spread of ropivacaine by a weight-based formula in a pediatric caudal block: a fluoroscopic examination. *Acta Anaesthesiol Scand* 2010; **54**: 562–565.
- 55 Thomas ML, Roebuck D, Yule C *et al.* The effect of volume of local anesthetic on the

- anatomic spread of caudal block in children aged 1–7 years. *Pediatr Anesth* 2010; **20**: 1017–1021.
- 56 Lundblad M, Lonnqvist PA, Eksborg S *et al.* Segmental distribution of high-volume caudal anesthesia in neonates, infants, and toddlers as assessed by ultrasonography. *Pediatr Anesth* 2011; **21**: 121–127.
- 57 Hubler M, Gäbler R, Ehm B *et al.* Successful resuscitation following ropivacaine-induced systemic toxicity in a neonate. *Anaesthesia* 2010; **65**: 1137–1140.
- 58 Bhananker SM, Ramamoorthy C, Geiduschek JM *et al.* Anesthesia-related cardiac arrest in children: update from the Pediatric Perioperative Cardiac Arrest Registry. *Anesth Analg* 2007; **105**: 344–350.
- 59 Morray JP, Geiduschek JM, Ramamoorthy C *et al.* Anesthesia-related cardiac arrest in children: initial findings of the Pediatric Perioperative Cardiac Arrest (POCA) Registry. *Anesthesiology* 2000; **93**: 6–14.
- 60 Ansermino M, Basu R, Vandebek C *et al.* Nonopioid additives to local anaesthetics for caudal blockade in children: a systematic review. *Pediatr Anesth* 2003; **13**: 561–573.
- 61 de Beer DA, Thomas ML. Caudal additives in children—solutions or problems? *Br J Anaesth* 2003; **90**: 487–498.
- 62 Veyckemans F, Van Obbergh LJ, Gouverneur JM. Lessons from 1100 pediatric caudal blocks in a teaching hospital. *Reg Anesth* 1992; **17**: 119–125.
- 63 Mauch J, Kutter AP, Madjdpour C *et al.* Electrocardiographic alterations during intravascular application of three different test doses of bupivacaine and epinephrine: experimental study in neonatal pigs. *Br J Anaesth* 2010; **104**: 94–97.
- 64 Lee JJ, Rubin AP. Comparison of a bupivacaine-clonidine mixture with plain bupivacaine for caudal analgesia in children. *Br J Anaesth* 1994; **72**: 258–262.
- 65 Motsch J, Böttiger BW, Bach A *et al.* Caudal clonidine and bupivacaine for combined epidural and general anaesthesia in children. *Acta Anaesthesiol Scand* 1997; **41**: 877–883.
- 66 Breschan C, Krumpholz R, Likar R *et al.* Can a dose of 2 microg.kg(-1) caudal clonidine cause respiratory depression in neonates? *Pediatr Anesth* 1999; **9**: 81–83.
- 67 Bouchut JC, Dubois R, Godard J. Clonidine in preterm-infant caudal anesthesia may be responsible for postoperative apnea. *Reg Anesth Pain Med* 2001; **26**: 83–85.
- 68 Fellmann C, Gerber AC, Weiss M. Apnoea in a former preterm infant after caudal bupivacaine with clonidine for inguinal herniorrhaphy. *Pediatr Anesth* 2002; **12**: 637–640.
- 69 Galante D. Preoperative apnea in a preterm infant after caudal block with ropivacaine and clonidine. *Pediatr Anesth* 2005; **15**: 708–709.
- 70 Hansen TG, Henneberg SW, Walther-Larsen S *et al.* Caudal bupivacaine supplemented with caudal or intravenous clonidine in children undergoing hypospadias repair: a double-blind study. *Br J Anaesth* 2004; **92**: 223–227.
- 71 Curatolo M, Petersen-Felix S, Arendt-Nielsen L *et al.* Epidural epinephrine and clonidine: segmental analgesia and effects on different pain modalities. *Anesthesiology* 1997; **87**: 785–794.
- 72 Krane EJ, Jacobson LE, Lynn AM *et al.* Caudal morphine for postoperative analgesia in children: a comparison with caudal bupivacaine and intravenous morphine. *Anesth Analg* 1987; **66**: 647–653.
- 73 Krane EJ. Delayed respiratory depression in a child after caudal epidural morphine. *Anesth Analg* 1988; **67**: 79–82.
- 74 Lonnqvist PA, Ivani G, Moriarty T. Use of caudal-epidural opioids in children: still state of the art or the beginning of the end? *Pediatr Anesth* 2002; **12**: 747–749.
- 75 Krane EJ, Tyler DC, Jacobson LE. The dose response of caudal morphine in children. *Anesthesiology* 1989; **71**: 48–52.
- 76 Campbell FA, Yentis SM, Fear DW *et al.* Analgesic efficacy and safety of a caudal bupivacaine-fentanyl mixture in children. *Can J Anaesth* 1992; **39**: 661–664.
- 77 Erol A, Tavlan A, Tuncer S *et al.* Caudal anesthesia for minor subumbilical pediatric surgery: a comparison of levobupivacaine alone and levobupivacaine plus sufentanil. *J Clin Anesth* 2008; **20**: 442–446.
- 78 Kumar TPS, Jacob R. A comparison of caudal epidural bupivacaine with adrenaline and bupivacaine with adrenaline and pethidine for operative and postoperative analgesia in infants and children. *Anaesth Intensive Care* 1993; **21**: 424–428.
- 79 Kelleher AA, Black A, Penman S *et al.* Comparison of caudal bupivacaine and diamorphine with caudal bupivacaine alone for repair of hypospadias. *Br J Anaesth* 1996; **77**: 586–590.
- 80 Prosser DP, Davis A, Booker PD *et al.* Caudal tramadol for postoperative analgesia in paediatric hypospadias surgery. *Br J Anaesth* 1997; **79**: 293–296.
- 81 Cook B, Doyle E. The use of additives to local anaesthetic solutions for caudal epidural blockade. *Pediatr Anesth* 1996; **6**: 353–359.
- 82 Vranken JH, Troost D, de Haan P *et al.* Severe toxic damage to the rabbit spinal cord after intrathecal administration of preservative-free S(+)-ketamine. *Anesthesiology* 2006; **105**: 813–818.
- 83 Vranken JH, Troost D, Wegener JT *et al.* Neuropathological findings after continuous intrathecal administration of S(+)-ketamine for the management of neuropathic cancer pain. *Pain* 2005; **117**: 231–235.
- 84 Becke K, Höhne C, Jöhr M *et al.* Stelungnahme: S (+)-Ketamin als Supplement zur Kaudalanästhesie im Kindesalter. *Anästhesiol Intensivmed* 2007; **48**: 299.
- 85 Flandin-Bléty C, Barrier G. Accidents following extradural analgesia in children. The results of a retrospective study. *Pediatr Anesth* 1995; **5**: 41–46.
- 86 Ecoffey C, Samii K. Neurologic complication after epidural anesthesia in a 15-year-old boy. *Ann Fr Anesth Réanim* 1990; **9**: 398.
- 87 Zeidan A, Narchi P, Goujard E *et al.* Postoperative nerve irritation syndrome after epidural analgesia in a six-year-old child. *Br J Anaesth* 2004; **92**: 146–148.
- 88 Breschan C, Krumpholz R, Jost R *et al.* Intraspinal haematoma following lumbar epidural anaesthesia in a neonate. *Pediatr Anesth* 2001; **11**: 105–108.
- 89 Busoni P, Sarti A. Sacral intervertebral epidural block. *Anesthesiology* 1987; **67**: 993–995.
- 90 Shin SK, Hong JY, Kim WO *et al.* Ultrasound evaluation of the sacral area and comparison of sacral interspinous and hiatal approach for caudal block in children. *Anesthesiology* 2009; **111**: 1135–1140.
- 91 Jöhr M, Sossai R. Colonic puncture during ilioinguinal nerve block in a child. *Anesth Analg* 1999; **88**: 1051–1052.
- 92 Amory C, Mariscal A, Guyot E *et al.* Is ilioinguinal/iliohypogastric nerve block always totally safe in children? *Pediatr Anesth* 2003; **13**: 164–166.
- 93 Frigon C, Mai R, Valois-Gomez T *et al.* Bowel hematoma following an iliohypogastric-ilioinguinal nerve block. *Pediatr Anesth* 2006; **16**: 993–996.
- 94 Lipp AK, Woodcock J, Hensman B *et al.* Leg weakness is a complication of ilio-inguinal nerve block in children. *Br J Anaesth* 2004; **92**: 273–274.
- 95 Smith T, Moratin P, Wulf H. Smaller children have greater bupivacaine plasma concentrations after ilioinguinal block. *Br J Anaesth* 1996; **76**: 452–455.
- 96 Jöhr M, Berger TM. Bloc pénien chez l'enfant. *Le praticien en anesthésie réanimation* 2006; **1**: 52–55.
- 97 Dalens B, Vanneville G, Dechelotte P. Penile block via the subpubic space in 100 children. *Anesth Analg* 1989; **69**: 41–45.
- 98 Soh CR, Ng SB, Lim SL. Dorsal penile nerve block. *Pediatr Anesth* 2003; **13**: 329–333.